

Ultrasound Evaluation of Changes in Uterine Position after Cesarean Delivery

Original
Article

Hager Said Ali, Abdel Haseib Salah Saad and Zakaria Fouad Sanad

Department of Obstetrics and Gynecology, Faculty of Medicine, Menoufia University, Egypt

ABSTRACT

Aim: To detect changes that occurs on uterine position after cesarean section on transvaginal ultrasound examination.

Materials and Methods: This case control study was carried out on (216) patients during the period from 2018, till 2020. The series was analyzed in three groups: patients who underwent cesarean delivery, patients who were parous but had not undergone cesarean delivery, and patients who were nulliparous. The axis of the uterus was determined on the transvaginal ultrasound. The uterine axis was categorized as anteverted, anteverted anteфлекed, retroverted, retroverted retroфлекed, anteverted retroфлекed, retroverted anteфлекed, and axial.

Result: The anteverted retroфлекed uterine position was common after CD (29.1% of CD group), rare in parous group (1.3%) and was not seen in nulliparous group. The higher number of anteverted retroфлекed uteri in the CD group was statistically significant ($p \leq 0.001$)

Conclusion: CD was associated with significant changes in position of uterus which can change the uterine flexion angle to a more retroфлекed position.

Key Words: CD (cesarean delivery), IUD (intrauterine device), NULLI (nullipara), US (ultrasound), VD (vaginal delivery)..

Received: 17th September 2020, **Accepted:** 4th August 2021

Corresponding Author: Hager Said Ali, Department of Obstetrics and Gynecology, Faculty of Medicine, Menoufia University, Egypt, **Tel.:** +20 10229 04154, **E-mail:** hager.elbasiony@gmail.com

ISSN: 2090-7265, August 2022, Vol.12, No. 3

INTRODUCTION

The incidence of cesarean deliveries has increased substantially over the past 25 years worldwide^[1]. In addition, the number of gynecologic procedures involving the uterus has risen^[2]. Copper intrauterine device (IUD) and levonorgestrel-releasing IUD placement has increased such that 14% of women are using an IUD worldwide^[3]. Reports have associated a retroфлекed uterine position with an increased surgical complication rate (eg, uterine perforation). It was already reported 30 years ago that a retroфлекed uterine position increases the risk of perforation during curettage, and that finding still holds true^[4]. The uterine position is traditionally defined by 2 angles: the flexion angle between the uterine body and the cervix and the version angle between the cervix and the vagina. In an anteфлекed uterus, the uterine fundus is angled toward the anterior abdominal wall. In contrast, in a retroфлекed uterus, the fundus is angled toward the sacrum^[5]. The angle between the axis of the trunk and the axis of the cervix in the longitudinal (longitudinal or sagittal) plane indicates uterine flexion. If this angle is 180 ° or less, the uterus is anteфлекed, and if it is more than 180 °, the uterus is in retroфлекion. The angle between the axis of the cervix and the axis of the vagina in the longitudinal (longitudinal or sagittal) plane indicates uterine version. If that angle is 90° or less, the uterus is in anteversion, and if it is more than

90°, the uterus is in retroversion^[6]. Uterine version together with flexion can be determined with imaging studies, such as in-office bedside ultrasonography (US). This easily obtained information is valuable to the gynecologist particularly when performing intrauterine procedures such as dilation and curettage, endometrial biopsy, saline infusion sonohysterography and insertion of an IUD^[5]. Pelvic ultrasound examination is a noninvasive, rapid and reliable tool with which to image internal genitalia in female infants, children and adolescents^[7].

AIM OF THIS STUDY

The aim of this study was to detect changes that occur on uterine position after caesarean section on transvaginal ultrasound examination.

PATIENT AND METHOD

This case control study was conducted on total number of 216 patients, divided in to three groups: 72 women who had one or more vaginal deliveries, 72 women who had one or more cesarean deliveries and 72 women who are nullipara.

The patients were selected from Obstetrics and Gynecology Outpatient Clinic, ShibinElkom Military Hospital and Birket El Sabaa hospital

Exclusion Criteria: Any case with any uterine surgery other than CD such as myomectomy, Fibroid more than 3 cm, Pelvic prolapsed, Endometriosis, pregnant women and history of pelvic inflammatory diseases.

Inclusion Criteria

Age from 20 to 45 years old and non pregnant female.

Method

Transvaginal ultrasound was performed on the uterus, reviewed and archived. Postpartum US images was accepted if the gynecologic TVUS scan was performed 2 weeks postpartum at the earliest because in the early normal puerperium, the position of the uterus can be variable^[8]. All patients should have an empty bladder before the transvaginal scan. The axis of the uterus was determined on the transvaginal images with the bladder as empty as possible. Ante flexion was defined as a flexion angle of 180 or less, whereas retro flexion was defined as a flexion angle of 180 or greater. The internal os was identified as the point of junction between the endometrial cavity and the cervical canal. An attempt was made to identify the location of the CD scar in the anterior uterine wall. Measurements of the CD scar myometrial width were made from the endometrium at the level of the scar to the outer margin of the uterus. When the CD scar showed myometrial thinning compared with adjacent lower segment myometrium it was described as thinned CD scar^[9]. Thinning was categorized as mild (less than one third of the myometrial thickness), moderate (more than one third to two thirds of the myometrial thickness), or severe (more than two thirds of the myometrial thickness) (Figure 1). Any fluid at the incision site was considered evidence of a niche (Figure 2)^[10]. Our definitions of sonographic uterine position are as follow:

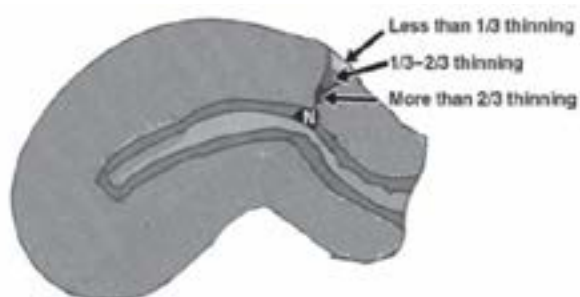


Fig. 1: Diagram shows how severity of myometrial thinning at cesarean section site was assessed

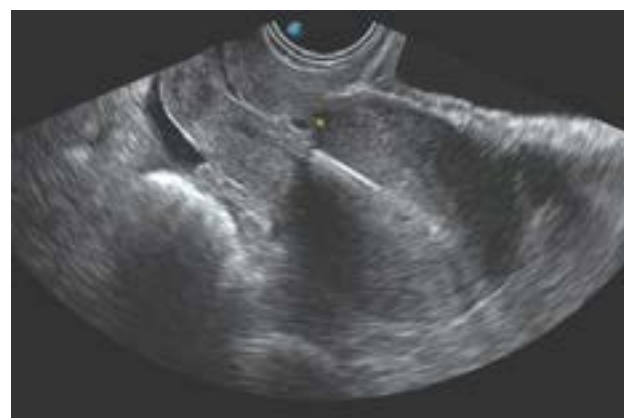

Fig. 2: Ultrasound image shows cervix and body of uterus are in same axis as ultrasound beam, with Cesarean scar defect (a filling defect) within the myometrium of the lower uterine segment

Anteversion was considered present when the transducer abutted the anterior border of the cervix and the cervix appeared on the viewer's right in the sagittal plane. Retroversion was considered present when in the sagittal plane the transducer abutted on the posterior border of the cervix and the cervix appeared on the viewer's left. Flexion was any deviation of the long axis of the endometrial lumen from the long axis of the cervix, resulting in anteriorly directed ante flexion and posteriorly directed retro flexion. Ante flexion was defined as a flexion angle of 180 or less, whereas retro flexion was defined as a flexion angle of 180 or greater.

The uterine axis was categorized as anteverted if the flexion of the uterus from the cervix was less than 15° (Figure 3), retroverted if the degree of retro flexion was less than 15°, anteverted ante flexed if the degree of ante flexion of the uterus from the cervix was greater than 15° (Figure 4), retroverted retro flexed if the degree of retro flexion of the uterus from the cervix was greater than 15° (Figure 5), anteverted retro flexed if the uterine fundus was flexed posteriorly to any extent (Figure 6), retroverted ante flexed when the cervix was retroverted but the fundus was flexed anteriorly (Figure 7), or axial when the uterine axis was in the same axis as the central angle of insonation (i.e., in the long axis of the vaginal probe) (Figure 8). Anteversion retro flexion was categorized as mild if the posterior angulation of the fundus was less than 15°, moderate if angulation was more than 15° but less than 80°, right angled if the fundal axis was approximately 90° to the cervical segment, and severe if the angulation was more than 100°.

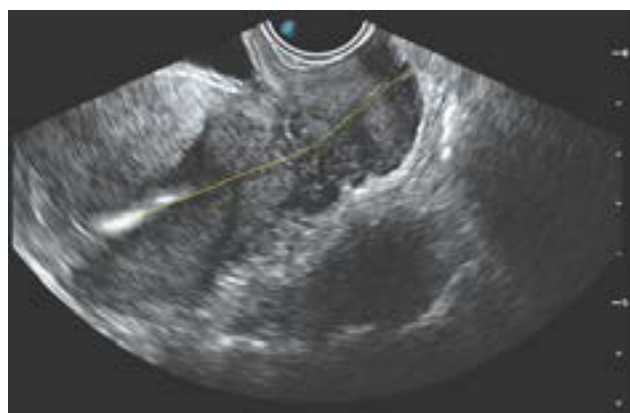

Fig. 3: Woman with anteverted uterus. Ultrasound image shows cervix and body of uterus are at almost at same axis. Yellow lines show the flexion angle measurement between the uterine cervix and uterine corpus (168.7)

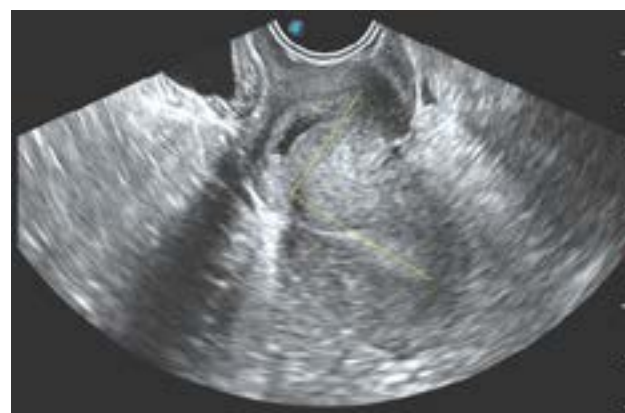

Fig. 6: Woman with anteverted retroflexed uterus. Ultrasound image shows cervix angled anteriorly and fundus is angled posteriorly and is at right-angle axis to cervix. Yellow lines show the flexion angle measurement between the uterine cervix and uterine corpus (279.9)

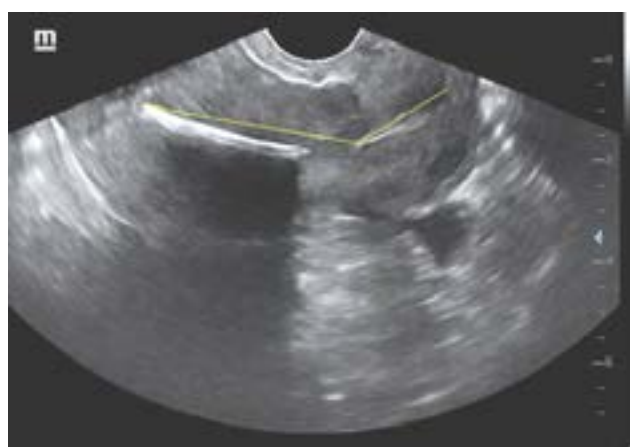

Fig. 4: Woman with anteverted anteflexed uterus. Yellow lines show the flexion angle measurement between the uterine cervix and uterine corpus. The angle between cervix and body of uterus greater than 15

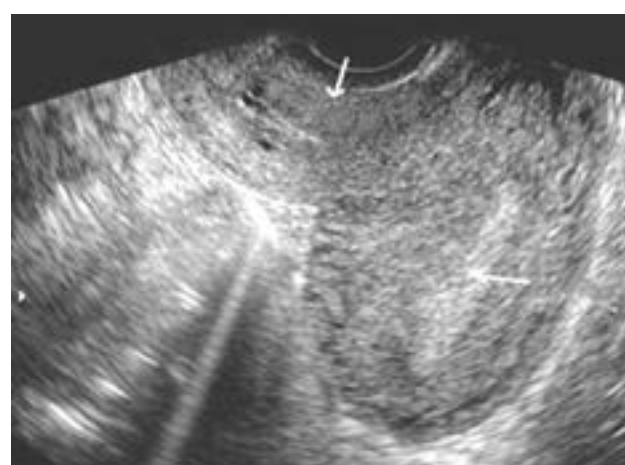


Fig. 7: Woman with retroverted anteflexed uterus. Ultrasound image shows cervix angled posteriorly and fundus is angled anteriorly

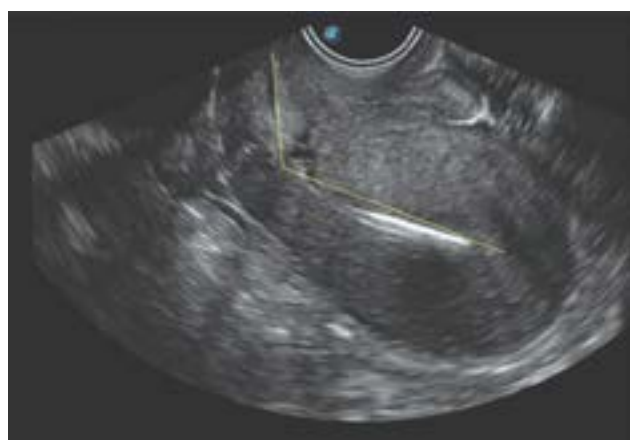

Fig. 5: Woman with retroverted retroflexed uterus. Yellow lines show the flexion angle measurement between the uterine cervix and uterine corpus. The angle between cervix and body of uterus greater than 15

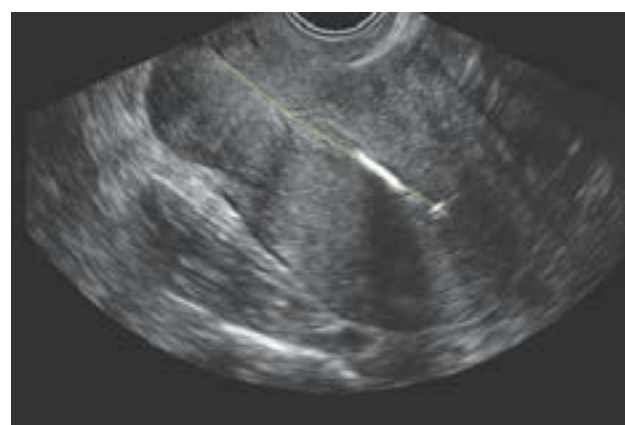

Fig. 8: woman with axially positioned uterus. Ultrasound image shows cervix and body of uterus are in same axis as ultrasound beam

STATISTICAL ANALYSIS

Data were fed to the computer and analyzed using IBM SPSS software package version 20.0.(Armonk, NY: IBM Corp).

Qualitative data were described using number and percent. Significance of the obtained results was judged at the 5% level.

The used tests were

1 - Chi-square test

For categorical variables, to compare between different groups

2 - Fisher's Exact or Monte Carlo correction

Correction for chi-square when more than 20% of the cells have expected count less than 5.

RESULT

Our study include 216 cases , 158 (73.1 %) uteri were anteverted, including 33 (15.2) that were also anteverted.

23 (10.6 %) uteri were retroverted, including 12 (5.5%) that were also retroflexed. 11(5.09%) uteri were axial. 22(10.1%) uteri were anteverted retroflexed "21(29.1%) uteri in CD group, 1(1.3%) uterus in VD group and no uteri with this position in Nulliparous group" and 2(0.9%) were retroverted anteverted. This higher number of anteverted retroflexed uteri in the CD group was statistically significant ($p \leq 0.001$) (Table 1). By measuring CD scar, the thinning was categorized as mild, moderate or severe. 24 cases were mild thinning, 16 cases were moderate, 7 cases were severe thinning, 13 cases had no myometrial thinning, and in 12 cases, CD scar was not seen (Table 2). By measuring CD scar and comparing it with the position of uterus, there were 5 anteverted retroflexed cases versus 19 cases of other positions in the mild CD scar group. 11 anteverted retroflexed cases versus 5 cases of other positions in the moderate CD scar group. And 5 anteverted retroflexed cases versus 2 cases of other positions in the severe CD scar group. CD scar thinning was seen in all cases of anteverted retroflexed position but was not seen in 12 cases of other positions. In all 21 anteverted retroflexed cases, there were thinning in scar but there were no thinning in 13 cases of other positions (Table 3).

Table 1: Uterine axis in Cesarean Delivery (CD), Nulliparous (Nulli), and Parous patients (VD)

	CD (n = 72)	VD (n = 72)	Nulli (n = 72)	Total (n = 216)	χ^2	P
Anteverted	36 ^a (50%)	46 ^a (63.8)	43 ^a (59.7%)	125(57.8)	3.000	0.223
Anteverted anteverted	7 ^a (9.7%)	11 ^a (15.2)	15 ^a (20.8%)	33(15.2)	3.434	0.180
Retroverted	2 ^a (2.7%)	4 ^a (5.5%)	5 ^a (6.9%)	11(5.09)	1.375	^{MC} p=0.638
Retroverted retroflexed	3 ^a (4.1%)	5 ^a (6.9%)	4 ^a (5.5%)	12(5.5%)	0.587	^{MC} p=0.930
Axial	3 ^a (4.1%)	4 ^a (5.5%)	4 ^a (5.5%)	11(5.09)	0.295	^{MC} p=1.000
Anteverted retroflexed	21 ^a (29.1)	1 ^b (1.3%)	0 ^b (0.0%)	22(10.1)	42.613*	<0.001*
Retroverted anteverted	0 ^b (0.0%)	1 ^b (1.3%)	1 ^b (1.3%)	2(0.92%)	1.251	^{MC} p=1.000

- χ^2 : Chi square test

- p: p value for comparing between the studied groups

- Data was expressed using number (percent %)

MC: Monte Carlo

*: Statistically significant at $p \leq 0.05$

Frequency in the same row with common small letters is not significant (i.e. Frequency with Different letters is significant).

Table 2: Degree of Myometrial Thinning in CD group

Degree of myometrial thinning	No. of cases (%)
Mild	24(33.3%)
Moderate	16(22.2%)
Severe	7(9.7%)
No thinning	13(18%)
Not seen	12(16.6%)

- Data was expressed using number (percent %).

Table 3: The Cesarean Delivery Scar (CD scar) in the Anteverted Retroflexed Position Compared with Scars in Other uterine Positions

Degree of myometrial thinning	Anteverted retroflexed position (n = 21)	Other positions (n = 51)	χ^2	P
Mild	5 ^a (23.8%)	19 ^a (37.2%)	1.210	0.271
Moderate	11 ^a (52.3)	5 ^b (9.8%)	15.601*	^{FE} p<0.001*
Severe	5 ^a (23.8%)	2 ^b (3.9%)	6.703*	^{FE} p=0.020*
No thinning	0 ^a (0%)	13 ^b (25.4%)	6.532*	^{FE} p=0.008*
Not seen	0 ^a (0%)	12 ^b (23.5%)	5.929*	^{FE} p=0.014*

χ^2 : Chi square test FE: Fisher Exact

p: p value for comparing between the studied group

*: Statistically significant at $p \leq 0.05$ Data was expressed using number (percent %) Frequency in the same raw with common small letters is not significant (i.e. Frequency with Different letters is significant).

DISCUSSION

Examination of uterine position by ultrasound on 72 patients who undergone CD comparing with 144 patients (72 nulliparous and 72 who underwent VD) shows that the anteverted retroflexed uterine position is common after CD (29.1% of CD group) and rare in the absence of CD (1.3%). The result demonstrated that CD was associated with significant changes in position of uterus. VD was not associated with a significant change in uterine flexion.

We also examined thinning of scar in CD group (72 cases). Cases with myometrial thinning at site of incision were 47 cases (65.3%), these cases including the three degrees (mild, moderate and severe). In all cases with anteverted retroflexed position, the CD scar was seen and there was myometrial thinning. In other positions, there was no myometrial thinning in 13 cases and scar was not seen in 12 cases.

In this current study we found an increase in number of anteverted retroflexed uterine positions and related it to thinned CD incisional scars. Also, the uterus frequently assumes an anteverted retroflexed position after CD because of adhesions that tethering the lower uterine segment to the anterior abdominal wall at the site of the incision. The adhesions elongate the cervix or lower uterine body, so changing the uterine position.

Our study agrees with Sanders and Parsons^[11] whose work was conducted on 641 patients with intact uteri. One hundred (15.6%) of the patients had undergone CD. Those patients were compared with the 408 (63.7%) parous patients who had not undergone CD and 133 (20.7%) patients who had never been pregnant. Of these, 27 uteri (27%) in the CD group had an anteverted retroflexed position, and 73 uteri in other positions. 4 (1%) uteri in VD group had an anteverted retroflexed position, and 404 uteri in other positions. And no uteri in nullipara group with this position. Sanders and Parsons^[11] referred the cause of changing uterine position to adhesion and thinning of the myometrium at the CD scar site, as in all cases of anteverted retroflexed position, the myometrium at CD incisional site was thinned.

Our study also agrees with^[5] who studied 173 women, the number of women with vaginal delivery was 107 of 173 (62%), and the number with cesarean delivery was 66 of 173 (38%). And the result of examination was 29% of patients in the cesarean delivery group had a change in uterine flexion from anteverted to retroflexed versus 13% of patients in the vaginal delivery group had a change in uterine flexion from anteverted to retroflexed.

CONCLUSION

Based on the results of present study we may conclude that:

Most uteri were anteverted and anteverted (73%). Retroverted retroflexed uteri made up 5.5% of the total and axially positioned uteri (5.09%). Retroverted anteverted uteri were seen in 0.92% of cases. Anteverted retroflexed uteri were seen in 10.1% (1.3% in VD group and 29.1% in CD group). We found an increase in anteverted retroflexed uterine position in the CD group, and related it to thinned CD incisional scars and adhesions. So all cases should undergo a TVUS examination specially who undergone CD before any gynecologic surgery or IUD placement to reduce the possibility of surgical complications.

CONFLICT OF INTERESTS

There are no conflicts of interest.

REFERENCES

1. Betrán, A. P., Ye, J., Moller, A. B., Zhang, J., Gülmezoglu, A. M., & Torloni, M. R. (2016). The increasing trend in caesarean section rates: global, regional and national estimates: 1990-2014. *PloS one*, 11(2), e0148343..
2. Twijnstra, A. R. H., Kolkman, W., Trimbo-Kemper, *et al.*, (2010). Implementation of advanced laparoscopic surgery in gynecology: national overview of trends. *Journal of minimally invasive gynecology*, 17(4), 487-492.

3. Buhling, K. J., Zite, N. B., Lotke, P., & Black, K. (2014). Worldwide use of intrauterine contraception: a review. *Contraception*, 89(3), 162-173.
4. Hefler, Lukas MD, Lemach, Andrea MD, Seebacher, *et al.*, The Intraoperative Complication Rate of Nonobstetric Dilation and Curettage, *Obstetrics & Gynecology*: June 2009 –
5. Kaelin Agten, A., Honart, A., Monteagudo *et al.*, (2018). Cesarean delivery changes the natural position of the uterus on transvaginal ultrasonography. *Journal of Ultrasound in Medicine*, 37(5), 1179-1183.
6. NIZIĆ, D., PERVAN, M., KOS, I., &Šimunović, M. (2014). Flexion and version of the uterus on pelvic ultrasound examination. *ActamedicaCroatica*, 68(3), 311-315org/10.4322/acr.2014.027.
7. Garel, L., Dubois, J., Grignon, *et al.*, (2001). US of the pediatric female pelvis: a clinical perspective. *Radiographics*, 21(6), 1393-1407.
8. Mulic-Lutvica, A., Bekuretsion, M., Bakos, *et al.*, (2001). Ultrasonic evaluation of the uterus and uterine cavity after normal, vaginal delivery. *Ultrasound in Obstetrics and Gynecology: The Official Journal of the International Society of Ultrasound in Obstetrics and Gynecology*, 18(5), 491-498.
9. Ofili-Yebovi, D., Ben-Nagi, J., Sawyer, E., *et al.*, (2008). Deficient lower-segment Cesarean section scars: prevalence and risk factors. *Ultrasound in Obstetrics and Gynecology: The Official Journal of the International Society of Ultrasound in Obstetrics and Gynecology*, 31(1), 72-77.
10. VikharevaOsser O and ValentinL(2010): Risk factors for incomplete healing of the uterine incision after cesarean section. *BJOG*; 117:1119–1126.
11. Sanders Rc and Parsons AK (2014):Anteverted retroflexed uterus: a common consequence of cesarean delivery. *AJR Am J Roentgenol*; 203:-W117–W124.