

## Detection of Breast Cancer Recurrence by Using Positron Emission Tomography with 18 Fluorodeoxyglucose (FDG-PET)-Computed Tomography (CT) and Tumor Markers

ALAA M. KOHLA, M.Sc.; MANAL F. HAMISA, M.D.; KHALID A. ABO DEWAN, M.D. and  
FATMA ZAKARIA, M.D.

*The Department of Radiodiagnosis and Medical Imaging, Faculty of Medicine, Tanta University*

### Abstract

**Background:** Breast cancer is responsible for nearly 15% of death in female cancer related death in western countries and is considered the second leading cause to death due to cancer in females. In Egypt, it is the most common cancer in female, representing about 38.8% of total cancer cases in women. Early diagnosis of recurrent breast cancer is crucial to selection of the most appropriate therapy. FDG-PET/CT has been used for diagnosis, staging, monitoring response to therapy, and restaging patients with breast cancer. Although FDG-PET/CT may have limited diagnostic value in detecting small primary breast tumors, in staging of the axillary region, and in detecting osteoblastic metastases, it is superior to conventional imaging modalities in detecting distant metastases and in monitoring response to therapy.

**Aim of Study:** To evaluate the role of PET/CT and tumor markers in detection of breast cancer recurrence in Clinical Radio-Diagnosis Department.

**Patients and Methods:** Twenty five female patients their age was from 22-67 years (mean 43 years) all with breast cancer history and elevated serum tumor markers after their initial diagnosis were retrospectively evaluated. PET/CT results were confirmed by further imaging, and follow-up. Changes in further management based on PET/CT were recorded.

**Results:** The patients' age was from 22-67 years. Most of them were (60%) were premenopausal. In this study, 92% had Infiltrating Ductal Carcinoma (IDC) while only 2 patients (8%) had Infiltrating Lobular Carcinoma (ILC), fourteen patients (56%) had recurrence of tumor, and 11 (44%) patients showed no further evidence of disease. Fourteen patients had abnormal PET/CT studies, and 11 patients had normal studies with an overall sensitivity, specificity, and accuracy of 85.7%, 81.8%, and 84%, respectively. PET/CT was compared with contrast-enhanced CT and had a higher sensitivity (85.7% vs. 71.4%), specificity (81.8% vs. 45.4%), and accuracy (84% vs. 60%). PET/CT was also compared with tumor markers and had a higher sensitivity (85.7% vs. 78.5%), specificity (81.8% vs. 18.1%), and accuracy (84% vs. 52%).

**Correspondence to:** Dr. Alaa M. Kohla, The Department of Radiodiagnosis and Medical Imaging, Faculty of Medicine, Tanta University

**Conclusion:** FDG-PET/CT was superior to conventional imaging modalities in diagnosis of breast cancer recurrence.

**Key Words:** PET-CT – Cancer breast – Increased tumor markers.

### Introduction

**ACCURATE** diagnosis and restaging of recurrent cancer breast helps in delivering the most proper strategy of therapy, this by recognizing patients with limited disease, so the curative treatment could benefit them. FDG-PET helped in diagnosis, staging and therapy monitoring, and thus breast cancer restaging [1]. FDG-PET has limited value in diagnosis of small primary breast cancer, axillary lymph nodes staging and in bone metastases diagnosis but still superior than other conventional imaging modalities in distant metastases diagnosis and also in therapy monitoring [2]. FDG-PET is very important in metastases diagnosis especially in the presence of new signs and symptoms or by significant increase of tumor markers (CA15-3, CEA) [3-7]. FDG-PET showed accuracy range between 87% to 90% in diagnosis of metastatic disease in asymptomatic breast cancer patients with significant increase tumor markers, while the accuracy in conventional imaging range between 50% to 78% [8].

PET/CT provides anatomic and metabolic imaging information which improve the accuracy of diagnosis and better management, this by accurate anatomical localization of functional data and providing combined PET/CT images [9].

The study was done for evaluation of PET/CT and tumor markers role in breast cancer recurrence detection in Clinical Radio-Diagnosis Department.

### Patients and Methods

This study will be performed at the Radio-Diagnosis Department and Clinical Oncology Department from December 2017 to December 2018.

#### I- Patients:

- All twenty five female patients included in this study are suspected clinically to have breast cancer recurrence after therapy either surgery or adjuvant therapy, and will be subjected to all the following:

- 1- History taking (age, name and sex).
  - 2- Clinical examination (local and general examination).
  - 3- Full laboratory investigations including tumor markers and histopathological results.
  - 4- Other imaging studies.
  - 5- PET/CT study done for detection of recurrence.
- **Inclusion criteria:** The patient should be diagnosed as breast cancer with one or more of the following indications of recurrence:
    - 1- Clinical examination.
    - 2- Tumor markers elevation (CEA and/or CA 15.3).
    - 3- Imaging study suspecting recurrence.
  - **Exclusion criteria:**
    - 1- Patients refusing the technique.
    - 2- Pregnancy and lactation.
    - 3- History of chemotherapy or radiotherapy within one month of the technique.
    - 4- Contraindicated patients to contrast agent.
    - 5- Patients with uncontrolled diabetes.
  - Informed written consent will be obtained after full explanation of the benefits and risks of the procedure from all patients.
  - Risks are uncommon.
  - The privacy of participants and confidentiality of data will be guaranteed during various phases of the study. The results will be used as scientific material only and will not be used by any legal authorities.

#### II- FDG-PET/CT imaging:

All studied patients underwent PET/CT using PET/CT system (Philips, Gemini, TF) with a 16 multi-slice CT scanner. Patients were asked to fast for 4-6 hours before F18-FDG injection. We measured level of blood glucose before injection of a F 18-FDG to be sure that level less than 190mg/dL. The tracer dose is 3.7-7.4MBq/kg. After injection,

whole-body FDG-PET was underwent at least 45 minutes after tracer injection.

#### III- Data analysis:

Specificity, sensitivity, accuracy, positive and negative predictive value for both PET/CT and contrast-enhanced CT were calculated for cancer recurrence diagnosis.

### Results

Breast cancer recurrence was detected in 14 (56%) patients, while 11 patients (44%) had no evidence of recurrence.

Table (1): Patients' characteristics of examined patients (50).

	No.	%
<b>Age:</b>		
≤40	18	22.5
>40	32	77.5
<b>Menstrual history:</b>		
Premenopausal	30	60
Postmenopausal	20	40
<b>FH:</b>		
NA	14	28
Negative	20	40
Positive	16	32
<b>Pathology:</b>		
IDC	46	92
ILC	4	8
<b>Hormonal receptors (ER &amp; PR):</b>		
Negative	4	8
Positive	46	92
<b>Stage and grade:</b>		
• <b>Stage:</b>		
I	10	20
II	26	52
III	14	28
• <b>Grade:</b>		
I	2	4
II	42	84
III	6	12
<b>Surgical treatment:</b>		
BCS	32	64
MRM	18	36
<b>Adjuvant treatment:</b>		
• <b>Chemotherapy:</b>		
No	2	4
Yes	48	96
• <b>Radiotherapy:</b>		
No	2	4
Yes	48	96
• <b>Hormonal treatment:</b>		
No	4	8
Yes	46	92
<b>Tumor marker on diagnosis (CA15.3):</b>		
Normal	32	64
High	18	36

*Patient-based analysis:* (Table 1):

Patients' age was from 22-67 years, with median age 43 years. The majority (60%) of our patients were pre-menopausal and (40%) were post-menopausal.

Regarding to the pathology of the studied patients, the majority (92%) had IDC while two patients (8%) had ILC. Five patients (20%) were stage I, 13 patients (52%) were stage II and 7 patients (28%) were stage III.

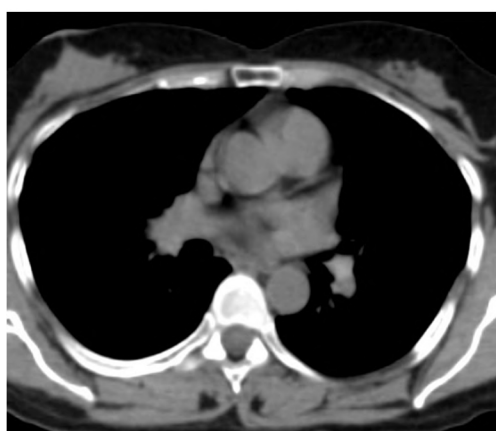As regards to tumor markers done at time of diagnosis, 9 patients (36%) presented by elevated tumor marker (CA1 5.3) while on time of recurrence

20 patients (80%) presented by elevated tumor marker (CA15.3) with sensitivity, specificity and accuracy of 78.5%, 18.1% and 52% respectively.

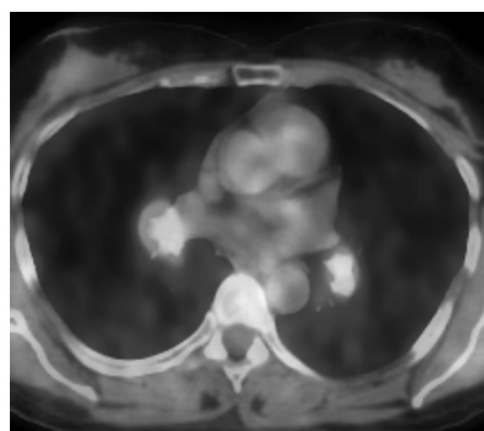
Among our studied patients who underwent routine imaging on suspected recurrence (e.g CT, Ultrasonography, mammography and Bone scan), 16 patients (64%) showed suspicious findings with sensitivity, specificity and accuracy of 71.4%, 45.4% and 60% respectively (Table 2). In this study, among 25 patients who underwent PET/CT studies, 14 patients had positive findings with sensitivity, specificity and accuracy of 85.7%, 81.8% and 84% (Table 2).

Table (2): (Sensitivity, specificity and accuracy) for different parameters (n=50).

	Follow-up				Sensitivity	Specificity	PPV	NPV	Accuracy
	Negative (n=11)		Positive (n=14)						
	No.	%	No.	%					
<i>Tumor marker:</i>									
N	8	18.2	12	21.4	78.57	18.18	55.0	40.0	52.0
H	36	81	44	78.6					
$\chi^2$ ( $^{FE}p$ )	0.041 (1.000)								
<i>Primary imaging</i>									
<i>at recurrence:</i>									
Negative	20	45.5	16	28.6	71.4	45.45	62.5	55.5	60
Positive	24	54.5	40	71.4					
$\chi^2$ ( $^{FE}p$ )	0.244 (0.697)								
<i>PET CT:</i>									
Negative	36	85.7	8	14.3	85.7	81.8	85.7	81.8	84
Positive	8	14.3	48	85.7					
$\chi^2$ ( $^{FE}p$ )	25.000* (<0.001*)								



(A)



(B)

Fig. (1): (A, B) PET-CT revealed glucose avid mediastinal LN.s.

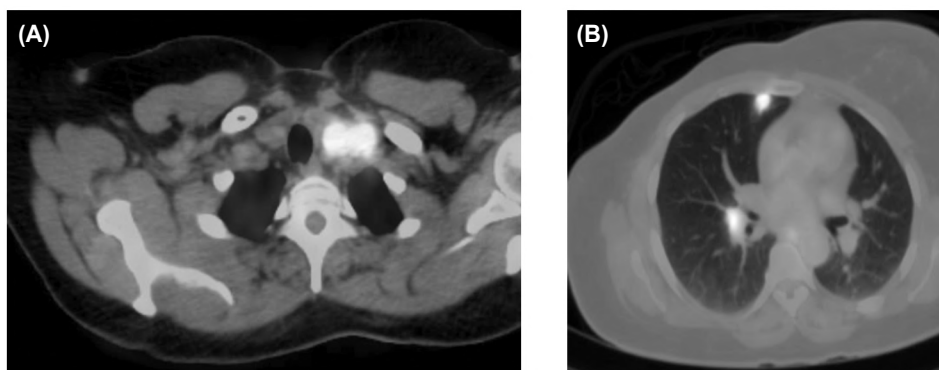


Fig. (2): (A, B) PET-CT revealed glucose avid mediastinal LN.s and right lung nodule.

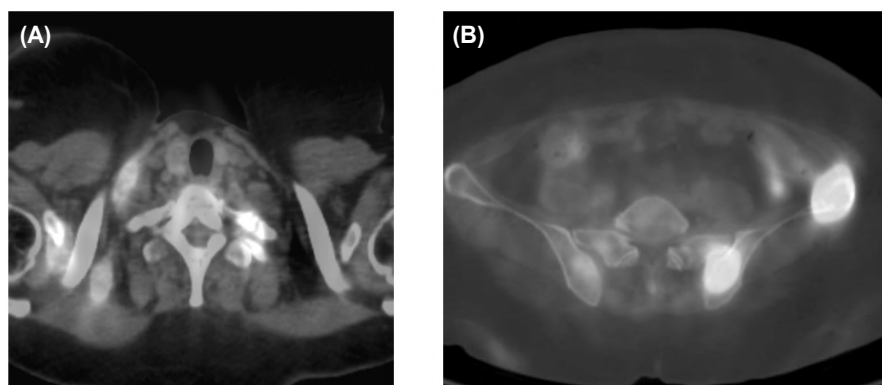


Fig. (3): PET-CT revealed multiple metastatic nodal and osseous lesions.

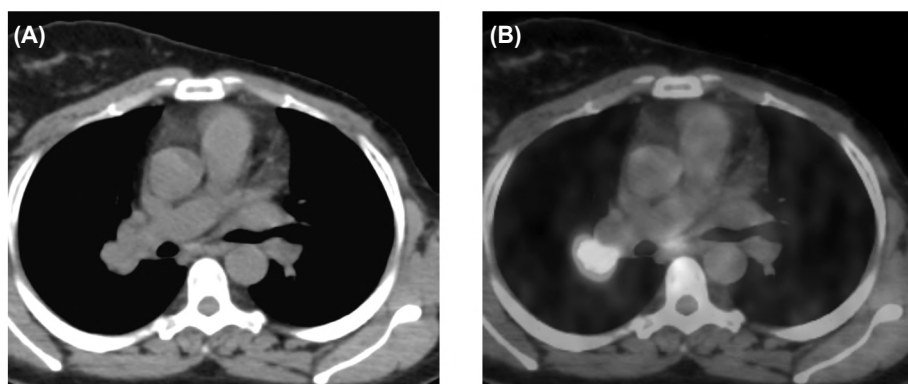


Fig. (4): PET-CT revealed glucose avid right para-hilar and mediastinal nodal lesion.

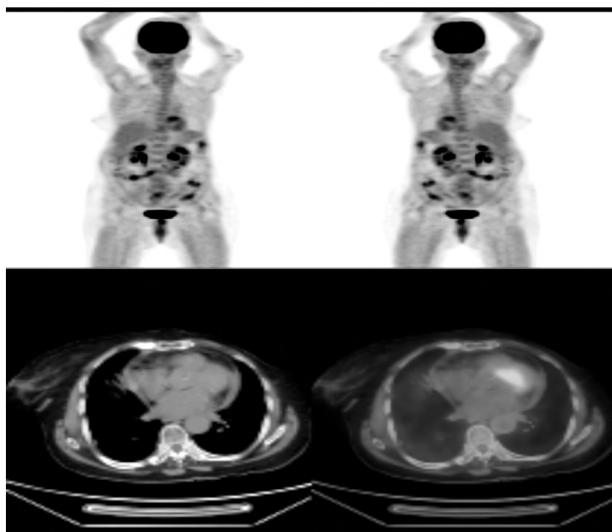


Fig. (5): PET-CT revealed free surveyed body from any metastatic foci.

## Discussion

FDG-PET is very important in accurate diagnosis of recurrent cancer breast, especially when other imaging modalities findings were inconclusive [10].

In the current study, the patient's age ranged from 22 to 67 years, with median age 43 years and this in agreement with Kim et al., [11].

Most of patients (60%) in this study were premenopausal and this may be due to poor prognosis and high risk of recurrence among this group of patients and this coincides with what reported by Carey et al., [12].

In this study, regarding to pathology of breast cancer IDC was the most common type (92%) and most of the patients (92%) were HR+ and this coincides with what reported by Ellis et al., as HR+ IDC are the most pathological type of cancer breast [13].

Advantage of FDG-PET compared to other imaging modalities is the screening of the whole body to detect recurrent breast cancer. The reported sensitivity and specificity of FDG-PET was 96% and 77%, respectively [11].

The diagnostic performance of FDG-PET was reported by Iasi et al., with sensitivity ranged from 55.6% to 100% (median, 92.7%), and specificity ranged from 0% to 100% (median, 81.6%) [14].

In this study, the sensitivity of FDG-PET/CT in diagnosis of breast cancer recurrence in patients with elevated serum tumor markers was high, at 85.7%. False-negative findings were due to small lesions and peritoneal metastases. The false-positive studies, with high FDG uptake, due to inflammatory changes and so the specificity was 81.8%.

In comparison of PET/CT imaging with CT, there was great improvement of sensitivity, specificity, accuracy, positive predictive value, and negative predictive value.

These results are matched with results of many studies as what reported by Grassetto et al., [15] and Flippi et al., [16].

Fueger et al., [17] also reported that there is improvement of PET/CT sensitivity and specificity when compared with PET (94% and 84% compared to 85% and 72%, respectively).

## Conclusion:

FDG-PET/CT was superior to conventional imaging modalities in diagnosis of breast cancer recurrence.

## References

- 1- WEIR L., WORSLEY D. and BERNSTEIN V.: The value of FDG positron emission tomography in the management of patients with breast cancer. *Breast J.*, 11: 204-9, 2005.
- 2- LIND P., IGERC I., BEYER T., REINPRECHT P. and HAUSEGGER K.: Advantages and limitations of FDG PET in the follow-up of breast cancer. *Eur. J. Nucl. Med. Mol. Imaging*, 31 (Suppl 1): S125-S134, 2004.
- 3- CZERNIN J.: FDG-PET in breast cancer: A different view of its clinical usefulness. *Mol. Imaging Biol.*, 4: 35-45, 2002.
- 4- EUBANK W.B. and MANKOFF D.A.: Evolving role of positron emission tomography in breast cancer imaging. *Semin. Nucl. Med.*, 35: 84-99, 2005.
- 5- SUAREZ M., PEREZ-CASTEJON M.J., JIMENEZ A., et al.: Early diagnosis of recurrent breast cancer with FDG-PET in patients with progressive elevation of serum tumor markers. *Q. J. Nucl. Med.*, 46: 113-21, 2002.
- 6- GALLOWITSCH H.J., KRESNIK E., GASSER J., et al.: F-18 fluorodeoxyglucose positron-emission tomography in the diagnosis of tumor recurrence and metastases in the follow-up of patients with breast carcinoma: A comparison to conventional imaging. *Invest. Radiol.*, 38: 250-6, 2003.
- 7- TATSUMI M., COHADE C., MOURTZIKOS K.A., FISHMAN E.K. and WAHL R.L.: Initial experience with FDG-PET/CT in the evaluation of breast cancer. *Eur. J. Nucl. Med. Mol. Imaging*, 33: 254-62, 2006.
- 8- SIGGELKOW W., RATH W., BUELL U. and ZIMNY M.: FDG PET and tumour markers in the diagnosis of recurrent and metastatic breast cancer. *Eur. J. Nucl. Med. Mol. Imaging*, 31 (Suppl 1): S118-24, 2004.
- 9- ZANGHERI B., MESSA C., PICCHIO M., GIANOLLI L., LANDONI C. and FAZIO F.: PET/CT and breast cancer. *Eur. J. Nucl. Med. Mol. Imaging*, 31 (Suppl 1): S135-S142, 2004.
- 10- EUBANK W.B., et al.: Detection of locoregional and distant recurrences in breast cancer patients by using FDG PET. *Radiographics*, 22 (1): p. 5-17, 2002.
- 11- KIM T.S., et al.: Fluorodeoxyglucose positron emission tomography for detection of recurrent or metastatic breast cancer. *World Journal of Surgery*, 25 (7): p. 829-34, 2001.
- 12- CAREY L.A., et al.: Race, breast cancer subtypes, and survival in the carolina breast cancer study. *JAMA*, 295 (21): p. 2492-502, 2006.
- 13- ELLIS I., et al.: Pathological prognostic factors in breast cancer. II. Histological type. Relationship with survival in a large study with long-term follow-up. *Histopathology*, 20 (6): p. 479-89, 1992.
- 14- ISASI C.R., R.M. MOADEL and M.D. BLAUFOX: A meta-analysis of FDG-PET for the evaluation of breast cancer recurrence and metastases. *Breast cancer research and treatment*, 90 (2): p. 105-12, 2005.

- 15- GRASSETTO G., et al.: 18F-FDG-PET/CT in patients with breast cancer and rising Ca 15-3 with negative conventional imaging: A multicentre study. *European Journal of Radiology*, 80 (3): p. 828-33, 2011.
- 16- FILIPPI V., et al.: The impact of FDG-PET/CT on the management of breast cancer patients with elevated tumor markers and negative or equivocal conventional imaging modalities. *Nuclear Medicine Communications*, 32 (2): p. 85-90, 2011.
- 17- FUEGER B.J., et al.: Performance of 2-deoxy-2-[F-18] fluoro-D-glucose positron emission tomography and integrated PET/CT in restaged breast cancer patients. *Molecular Imaging and Biology*, 7 (5): p. 369-76t, 2005.

## دراسة دور الأشعة المقطعية بالمسح البوزيتروني ودلالات الأورام في تحديد إرتجاع أورام الثدي لدى المرضى

يعتبر سرطان الثدي هو أكثر أنواع السرطانات التي تصيب النساء اللواتي يعشن في البلدان الغربية ويشكل تحدياً كبيراً للأبحاث المتعلقة بالأورام وهو المسؤول عن حوالي ١٥٪ من جميع وفيات النساء من السرطانات في البلدان الغربية، وهو ما يمثل السبب الرئيسي الثاني للوفيات المتعلقة بالسرطان، ولا يؤثر على كبار السن فحسب، بل العديد من المرضى صغار السن، في مصر يعد سرطان الثدي هو الأكثر شيوعاً بين النساء، حيث يمثل ٣٨.٨٪ من إجمالي حالات السرطان لدى النساء.

على الرغم من التقدم الكبير في وسائل العلاج، فقد ظل إرتجاع الورم مشكلة كبيرة في علاج سرطان الثدي. وتشير التقديرات إلى أن ما يصل إلى ٣٥٪ من مرضى سرطان الثدي الأساسي بعد العلاج الجذري سوف يتطور في نهاية المطاف إلى الإنتكاس.

في وجود إشتباه في إنتكاس المرض، عادة ما يرتبط بالإرتفاع المستمر لدلالات الأورام، أو الشك في طرق التصوير التقليدية، أو الأعراض الإكلينيكية الإيجابية أو الفحوصات الجسدية، فمن المستحسن المضي قدماً في مزيد من الفحوصات.

في الدراسة الحالية، كانت حساسية المسح البوزيتروني على الجسم مع الأشعة المقطعية لتشخيص الورم المتكرر في مرضى سرطان الثدي مع إرتفاع دلالات الأورام تصل إلى ٨٥.٧٪.

بالمقارنة مع الأشعة المقطعية، المسح البوزيتروني على الجسم مع الأشعة المقطعية حساسية محسنة، وخصوصية، ودقة، وقيمة تنبؤية إيجابية، وقيمة تنبؤية سلبية وتأثير على تغيير خطة علاج مرضى سرطان الثدي.