



Clinical, Haematological and Biochemical Findings in Sheep Naturally Infected with *Dermatophilus congolensis*

Aynur Simsek^{1*}, Akin Kochan¹ and Simten Yesilmen Alp²

¹ Department of Internal Medicine, Veterinary Faculty, Dicle University, Diyarbakir, Turkey.

² Department of Microbiology, Veterinary Faculty, Dicle University, Diyarbakir, Turkey.



CrossMark

Dermatophilus congolensis infection in sheep is manifested as matted tufting, entanglement, hardening and loss of wool, and thickening and itching of the skin, altogether which eventually results in economic losses. We investigated the clinical, hematological and biochemical findings in sheep naturally infected with *Dermatophilus congolensis*. For this purpose, 35 infected Akkaraman sheep (aged: 3-4 years, belonging to a flock of 200 animals) were referred to Prof. Dr. Servet SEKIN Polyclinic of the Dicle University, Veterinary Faculty with various skin problems were included. The infected sheep presented with crusted skin lesions, matted wool tufts, alopecia, and pruritus. Their biochemical serum analyses revealed increased serum alkaline phosphatase, alanine aminotransferase, lactate dehydrogenase, blood urea nitrogen, total protein, albumin and calcium levels, and decreased creatinine, sodium and potassium levels in comparison with the control animals. The infected animals were treated with parenteral amoxicillin/clavulanic acid (Synulox®-Zoetis; 8.75 mg/kg body weight, i.m., once daily for 5 days) and local povidone-iodine (Batimer®-Esmira) administration, and observed for response to the treatment regimen. We found that *Dermatophilus congolensis* infection causes skin and wool damage in sheep, along with alteration in the serum biochemical parameters.

Keywords: Clinical findings, *Dermatophilus congolensis*, Haematology, Serum biochemistry, Sheep.

Introduction

Dermatophilus congolensis (*D. congolensis*) is a Gram-positive pleomorphic bacterium, which is the etiological agent of dermatophilosis, mainly manifested as acute, subacute or chronic exudative dermatitis in animals [1, 2]. First reported by Van Saceghem in 1915 in cattle raised in Belgian Congo [3], dermatophilosis, or “dermo” and “lumpy wool” [1], is the most common disease among cattle, sheep, goats and horses, with occasional occurrence in cats, dogs and wild animals [4, 5].

Frequently observed in the tropical and subtropical climates [3, 6-8], dermatophilosis

is particularly common among undernourished animals with a poor body condition score [9], with the involvement of mechanical skin damage, rainfall, tick infestations, and factors affecting host immunity in the pathogenesis of the disease [4, 10, 11].

Dermatophilosis lesions, which are characterized by dermal inflammation, serous exudation, and scab and crust formation, may manifest as a localized or generalized distribution, depending on the impact of predisposing factors. Clinical findings associated with this disease include matted tufting, entanglement, hardening and loss of wool and thickening and itching of the skin [9].

The presumptive and confirmatory diagnoses of this disease are based on the dominant clinical signs, direct microscopic observations of Giemsa-stained smears prepared from scab/crust material, isolation and identification of *D. congolensis* via cultivation from skin lesions on bacteriological media, followed by serological tests and polymerase chain reaction analyses [4, 6, 9, 12-14].

Although past studies indicate the use of various local and parenteral antimicrobials for the treatment of animals infected with *D. congolensis*, it has been indicated that most of the available local treatments are ineffective [6] and parenteral treatment is mostly complicated, eventually leading to disease recurrence [5, 10].

Considering that dermatophilosis causes significant economic losses through decreased meat, milk and wool production, reduced hide and wool quality, treatment costs, and mortality [1, 4, 9], it is suggested to closely monitor this disease in Turkey [8].

Despite numerous reports on the occurrence of dermatophilosis in diverse animal species, to the best of our knowledge, there is no published report on the haematological and biochemical parameters in sheep that have been naturally infected with *D. congolensis*. In view of the paucity of information on this subject, the present study attempted to demonstrate the continued existence of this disease in the Diyarbakır province and its vicinity, previously reported by Sekin *et al.* [9] and to determine the clinical signs and haematological and biochemical parameters associated with this disease in infected sheep.

Materials and Methods

Ethical considerations

In the study, diagnostic and therapeutic applications were made and no experimental applications were made. Ethical approval from a committee was not necessarily required.

Animals and Sample collection

The study subjects included 35 infected Akkaraman sheep (aged: 3-4 years, belonged to a flock of 200 animals) were referred to Prof. Dr. Servet Sekin Polyclinic of Dicle University, Veterinary Faculty with signs of matted tufting and loss of wool as well as scabbing, crusting, thickening, hardening and itching of the skin. The control animal group consisted of 10 Akkaraman sheep belonging to the same flock, who were

housed in a separate area to prevent contact with the infected animals.

Anamnesis revealed that both the infected and healthy animals had undergone antiparasitic treatment nearly 2 months before their admittance to the clinic.

At the request of the owner, the flock was visited, and non-infected animals who were housed separately as well as the infected animals were clinically examined for body temperature, heart rate and respiratory rate and skin lesions.

Following the clinical examination, both uninfected animals and 10 heavily diseased animals were sampled for jugular venous blood, which was used for haematological and biochemical analyses. Furthermore, skin swabs of uninfected animals and skin scrapings from the lesions of these 10 heavily diseased animals were collected for mycological and bacteriological examinations.

Haematological and biochemical analyses

Haematological analyses were performed to determine the white blood cell (WBC) and red blood cell (RBC) counts, haemoglobin (Hgb) level, and haematocrit (Htc) value. Biochemical analyses were conducted to determine the levels of serum aspartate aminotransferase (AST), alanine aminotransferase (ALT), alkaline phosphatase (ALP), lactate dehydrogenase (LDH), blood urea nitrogen (BUN), creatinine (Cre), total protein (TP), albumin (Alb), glucose (Glu), calcium (Ca), phosphorus (P), sodium (Na), potassium (K) and chlorine (Cl).

Mycologic and bacteriologic examinations

The skin scrapings used for mycological examination were inoculated onto Sabouraud dextrose agar after treatment with 10% potassium hydroxide. The inoculated plates were maintained at the room temperature for 15 days. Skin swabs of the uninfected animals were also inoculated onto Sabouraud's dextrose agar, and the inoculated plates were incubated at the room temperature for 15 days.

The skin scrapings and swabs used for bacteriological examination were prepared using the Haalstra's method. The samples were first treated with sterile distilled water and then maintained at the room temperature for 3-5 h. Next, the samples were inoculated onto 5% sheep blood agar and incubated at 37°C under an atmosphere of 5-10% CO₂ for 24-48 h. At the end

of the incubation period, the colonies observed to have grown on the plates were gram-stained for microscopic examination. Biochemical analyses, including tests for catalase, gelatine hydrolysis, nitrate reduction, urea, glucose, mannitol, lactose and indole tests, were performed for species identification [15, 16].

The susceptibility of the isolates to various antimicrobials was determined by the disk diffusion method, as described by Bauer et al. [17]. For this purpose, penicillin G (10 IU), ampicillin (10 µg), penicillin/novobiocin (40 µg), amoxicillin/clavulanic acid (30 µg), enrofloxacin (5 µg), oxytetracycline (30 µg), danofloxacin (5 µg), cefoperazone (30 µg), sulbactam/ampicillin (20 µg), doxycycline (30 µg), ceftiofur (30 µg), amoxicillin (25 µg), cloxacillin (5 µg) and spectinomycin (100 µg) disks were used [18]. The results of the disk diffusion tests were assessed based on the interpretive criteria published by the Clinical and Laboratory Standards Institute [19].

Statistical analysis

The data obtained in the present study was finally statistically analysed with the SPSS 16.0 windows program. Differences between the groups were compared with independent t-test. Data were expressed as the mean \pm standard error of the mean (SEM). $P < 0.05$ was considered to be statistically significant.

Results

Clinical findings

All sheep in the control group showed normal appetite and no skin lesions were observed in the physical examination. The body temperature and respiratory and heart rates of these animals were normal.

During the clinical examination of the infected animals, typical exudative lesions, including scabbing/crusting, thickening, hardening, cracking and itching of the skin and matted tufting and loss of wool were observed in several body areas, with a primary localization in the head region and along the back (Fig. 1). The heart and respiratory rates and the body temperature of the animals were within the normal reference range.

During clinical examinations of uninfected and infected animals, no ectoparasites were observed on the skin.

Haematological and biochemical findings

Haematological examination of the blood samples revealed that the infected animals showed lower WBC counts and Hgb and Htc values, with higher RBC counts relative to that in the control group, albeit the differences between the 2 groups were statistically insignificant (Table 1).

The biochemical analyses of the serum samples revealed that the ALP, AST, ALT, LDH, BUN, TP, Alb, and Ca levels were higher, and the Cre, Glu, P, Na, K and Cl levels were lower in the infected group relative to that in the control group. The differences between the two groups with respect to the AST, Glu, P and Cl levels were statistically insignificant, while the ALP, ALT, LDH, BUN, Cre, TP, Alb, Ca, Na and K levels differed significantly between the infected and control groups (Table 2).

Mycologic and bacteriologic findings

The mycological examinations of skin swabs collected from the control group were negative and *D. congolensis* was not detected in the bacteriological examination.

The results of the mycological examination of the skin scab/crust samples on day 15 were negative. At the end of 48 h, beta-haemolytic, rough (R), dry, greyish-yellow-coloured, embedded colonies, of approximately 1-mm diameter were observed on the agar plates. Light microscopy examination of the gram-stained smears prepared from these colonies demonstrated the presence of gram-positive, filamentous organisms with branch-like body and coccoids displaying the characteristic tram track-like appearance (Fig. 2).

The biochemical test results revealed that the causative agent was catalase (+), gelatine hydrolysis (+), nitrate reduction (+), urea (+), glucose (+), mannitol (+), lactose (-) and indole (-).

The antibiogram results demonstrated that the isolates were susceptible to amoxicillin/clavulanic acid; moderately susceptible to sulbactam/ampicillin, doxycycline and spectinomycin; and resistant to the other antibiotic groups tested.

The sheep diagnosed with dermatophilosis were treated with parenteral amoxicillin/clavulanic acid (Synulox®-Zoetis; 8.75 mg/kg body weight, i.m., once daily for 5 days) and local povidone-iodine (Batimer®-Esmira) administration.

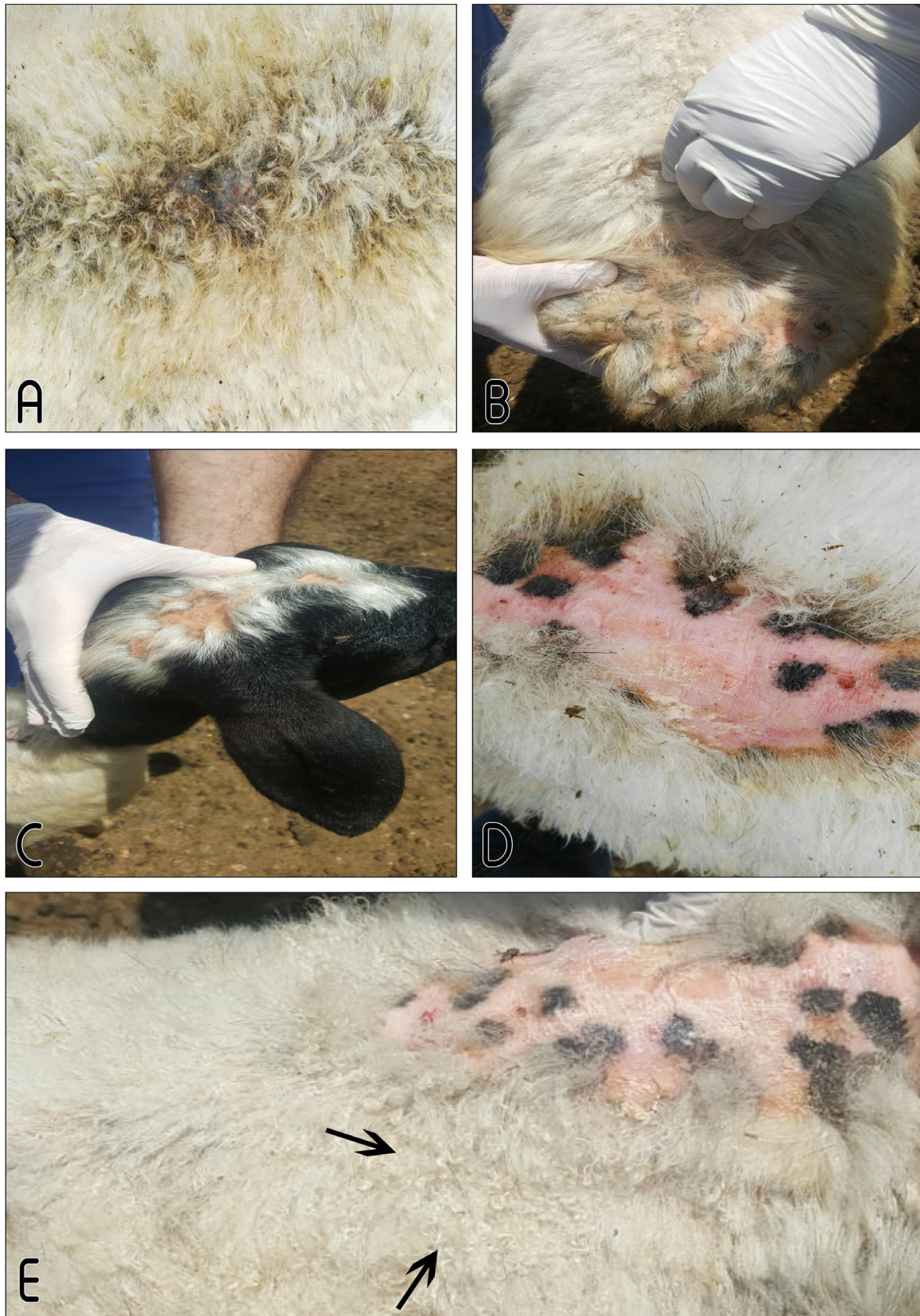


Fig. 1. Clinical findings of sheep naturally infected with *D. congolensis*. A) Dermatitis is observed on the back. B) Alopecia is observed on the tail (C), head (C) and back. D) Alopecia along the back. (E) Matted tufting of the wool is observed on the back (arrow).

TABLE 1. Hematological parameters in healthy sheep and those naturally infected with *D. congolensis* (mean \pm SEM).

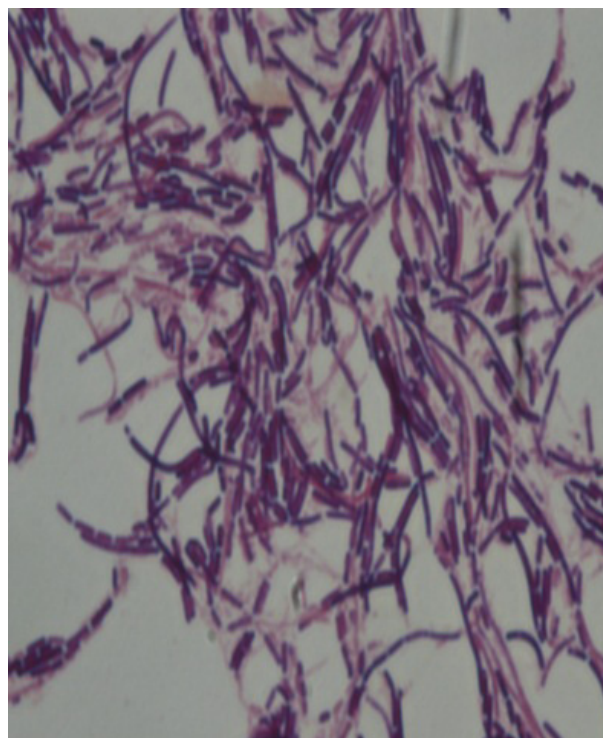
Parameters	Control (n=10)	Infected sheep (n=10)	P value
WBC ($\times 10^3/\mu\text{L}$)	12.38 \pm 0.77	11.24 \pm 0.47	0.22 ^{ns}
RBC ($\times 10^6/\mu\text{L}$)	8.68 \pm 0.39	9.07 \pm 0.48	0.54 ^{ns}
Hgb (g/dL)	8.86 \pm 0.35	7.99 \pm 0.35	0.09 ^{ns}
Htc (%)	25.96 \pm 0.83	25.86 \pm 1.09	0.94 ^{ns}

ns: Not significant.

TABLE 2. Serum biochemical parameters in healthy sheep and those naturally infected with *D. congolensis* (mean \pm SEM).

Parameters	Control (n=10)	Infected sheep (n=10)	P value
ALP (U/L)	57 \pm 10.31	104 \pm 15.42	0.02*
AST (U/L)	105.60 \pm 4.13	126.80 \pm 9.12	0.06 ^{ns}
ALT (U/L)	21 \pm 1.45	27.60 \pm 2.29	0.03*
LDH (U/L)	338.9 \pm 14.39	524.2 \pm 31.78	0.00***
BUN (mg/dL)	18.49 \pm 1.26	34.56 \pm 1.17	0.00***
CRE (mg/dL)	0.64 \pm 0.02	0.50 \pm 0.03	0.00**
TP (g/dL)	6.45 \pm 0.13	7.72 \pm 0.18	0.00***
Alb (g/dL)	2.78 \pm 0.07	3.06 \pm 0.07	0.01*
Glu (mg/dL)	55.60 \pm 1.50	51.50 \pm 3.44	0.3 ^{ns}
Ca (mg/dL)	8.37 \pm 0.18	10.29 \pm 0.27	0.00***
P (mg/dL)	6.01 \pm 0.35	5.38 \pm 0.36	0.23 ^{ns}
Na (mEq/L)	146.50 \pm 1.39	141.80 \pm 0.66	0.01**
K (mEq/L)	4.89 \pm 0.12	4.44 \pm 0.09	0.01**
Cl (mEq/L)	110.30 \pm 1.10	109.50 \pm 0.83	0.57 ^{ns}

ns: nonsignificant. * p<0.05. ** p<0.01. *** p<0.001.

**Fig. 2. Microscopic image of *D. congolensis* bacteria. Gram stain of a colony taken from on the blood agar. Septate filaments and coccoid forms are observed.**

Discussion

Dermatophilosis, which is frequently encountered in high-rainfall zones, causes significant economic loss in sheep flocks. Known to be a skin saprophyte that can survive for 3–4 years in hair follicles and dry skin crusts, *D. congolensis* causes disease once its motile zoospores are activated with the wetting of the host skin during rainy and humid weather. Furthermore, several stress factors such as parturition, lactation and inadequate nutrition are reported to encourage the pathogenesis of this disease [20]. In this study, although the infected animals were admitted to the polyclinic in May, anamnesis revealed that the disease was first detectable nearly 2 months before their admittance. The occurrence of the disease after the winter season was attributed to the animals having been kept in a closed environment for a long period as well as to the stress factors related to parturition, lactation and malnourishment along with wetting of the skin due to rainfall.

The reported clinical symptoms associated with ovine dermatophilosis include matted tufting, entanglement, hardening and loss of wool and the thickening and itching of the skin [9, 21]. In the present study, the infected animals manifested with typical exudative lesions in several portions of the body, primarily in the head region and along the back, as well as pruritus, scabbing, crusting, thickening, hardening and cracking of the skin, along with matted tufting and the loss of wool.

Abdo and Pal [22] determined the normal body temperature, heart rate and respiratory rate values in sheep and goats infected with *D. congolensis*. Similarly, in the present study, the body temperature and the heart and respiratory rates of the infected animals fell within the reference range.

Olaogun and Jeremiah [23] reported that, in cattle infected with dermatophilosis, the RBC counts, Hgb concentrations and Htc values decreased, while the WBC counts increased with increasing severity of the infection. Tresamol and Saseendranath [24] determined that, when compared with the control animals, cattle with dermatophilosis showed lower mean WBC and RBC counts and Hgb concentrations. In agreement with these previously reported findings, Tresamol and Saseendranath [24], in the present study, it

was ascertained that, when compared with the control group, the mean WBC counts and Hgb and Htc levels were lower in the sheep infected with dermatophilosis. The differences observed between the two groups for the haematological parameters investigated were found to be statistically insignificant ($p > 0.05$), and the values determined in both groups fell within the reference range.

On the other hand, Olaogun and Onwuzuruike [7] reported that the serum ALP and AST levels increased in cattle with dermatophilosis, while Tresamol and Saseendranath [24] reported ALP levels above the reference range and AST levels within the reference range, excluding cattle aged <2 years. In the present study, in agreement with a previously reported paper, Tresamol and Saseendranath [24], we ascertained that the serum AST levels of the infected animals fell within the reference range and did not show any statistically significant difference relative to those of the control group ($p > 0.05$). Similar to previous research by Olaogun and Onwuzuruike [7], the ALP levels were found to have increased in the infected animals, and, when compared to the control group, this increase was found to be of statistical significance ($p < 0.05$). The ALT and LDH levels of the infected animals were found to significantly differ from those of the control animals ($p < 0.05$ and $p < 0.001$, respectively). The serum ALP, ALT and LDH levels of the infected group were higher than those of the control group, which was considered to be related to skin irritation and stress-induced corticosteroid increase [7] as well as toxic hepatitis [25, 26].

While Olaogun and Onwuzuruike [7] reported serum BUN levels below the reference range in cattle infected with *D. congolensis*, Tresamol and Saseendranath [24] reported higher BUN levels and lower Cre levels in infected animals, in comparison to the control group. Similarly, the results of the present study demonstrated increased mean BUN levels ($p < 0.001$) and decreased Cre levels ($p < 0.01$) in the infected animals. The increase in the BUN level is not parallel with the increase in the Cre levels, suggesting that the increase was unrelated to renal damage, in conformance with a previous research [24]. The high level BUN and low Cre values in the infected sheep may be associated with protein catabolism due to the underlying stress condition.

While Tresamol and Saseendranath [24] determined that the Alb levels decreased, with no significant alteration in the serum TP concentrations in bovine dermatophilosis, some other researchers [7, 26, 27] reported reduced serum TP levels. Barre et al. [27] suggested that reduced TP levels resulted from anorexia, decreased Alb synthesis and proteinuria. In the present study, the mean TP and Alb concentrations in the infected animals were higher than those in the control group ($p < 0.001$ and $p < 0.05$, respectively). Hyperproteinemia in the infected sheep could be related to hyperalbuminemia and the increase in the production of immunoglobulins as a result of immune response by the animals to the infection. Although none of the sheep were clinically dehydrated, subclinical dehydration was suspected in the light of high albumin values.

While Gbodi [28] reported that the serum Ca levels did not alter in calves infected with dermatophilosis, Hamid and Musa [26] determined decreased serum Ca levels. In the present study, the infected sheep were ascertained to possess serum Ca levels higher than those of the control sheep. Thus, our results differed from some previously reported findings [26, 28]. Since the protein concentration, especially albumin, affects total calcium concentration [29], the higher Ca level in the infected sheep may be associated with a high Alb level.

Gbodi [28] reported that *D. congolensis* infection caused a slight decrease in serum Na concentrations. Similarly, the results of the present study demonstrated that the serum Na and K concentrations in the infected sheep were lower than those in the control sheep ($p < 0.05$). These results can be attributed to hyperproteinemia, which artifactually decreased the Na and K levels in the serum [30, 31].

Previous researches have proven the effectiveness of parenteral penicillin/streptomycin [9, 21, 32] and oxytetracycline [1, 15, 22, 32, 33] administration in the treatment of *D. congolensis* infection. Local treatment with antibiotic [1, 9] and antiseptic [15, 32] solutions have also been reported to be applied together with parenteral antibiotics, suggesting that, although local treatment has a limited effect, it provides an extra benefit in the control of the disease [4].

In the present study, as the antibiogram

results revealed that the isolates were susceptible to amoxicillin/clavulanic acid, parenteral amoxicillin/clavulanic acid (Synulox®-Zoetis; 8.75 mg/kg body weight, i.m., once daily for 5 days) was administered for the treatment. In addition to parenteral antibiotic administration, povidone-iodine (Batimer®-Esmira) was employed locally, and the infected animals were observed to respond to this treatment regimen.

Conclusion

D. congolensis infection can cause matted tufting, loss of wool and, the scabbing, crusting, thickening, hardening and itching of the skin, along with alteration in the serum biochemical parameters in sheep. Moreover, parenteral amoxicillin/clavulanic acid and local povidone-iodine administration were found to be effective in the treatment of ovine dermatophilosis.

Acknowledgement

For all staff in the department

Conflict of interest

The authors declare that they have no conflict of interest

Funding

No funding

References

1. Wabacha, J.K., Mulei, C.M., Gitonga, N.P., Njenga, M.J., Thaiyah, A.G. and Nduhiu, J. Atypical dermatophilosis of sheep in Kenya. *J. S. Afr. Vet. Assoc.*, **78**, 178-182 (2007). DOI: 10.4102/jsava.v78i3.314.
2. Walter, A., Paixao, A., Martinez, S. and Espinosa, I. Occurrence of bovine dermatophilosis in Huambo province, Angola. *Rev. Salud. Anim.*, **3**, 1-12 (2017).
3. Marchot, P.H. and Leroy, P. A dermatophilosis outbreak in Southern Sudan treatment trial with terramycin long activity. *Ann. Rech. Vet.*, **18**, 69-72 (1987).
4. Gebreyohannes, M. and Gebresselassie, M. An overview on dermatophilosis of animals: a review. *J. Anim. Sci. Adv.*, **3**, 337-344 (2013).
5. Nath, D.B., Ahasan, M.S., Rahman, M.S. and Huque, A.K.M.F. Prevalence and therapeutic management of bovine dermatophilosis. *Bangladesh Res. Pub J.*, **4**, 198-207 (2010).

6. Domingues, P.F., Guerra, S.T., Paula, C.L., Alves, A.C., Bolanos, C.A.D., Morais, A.B.C.D., Riseti, R.M., Colhado, B.S., Portilho, F.V.R., Caxito, M.S., Listoni, F.J.P., Oliveira, D.O. and Ribeiro, M.G. Successful therapy in unusual generalized *Dermatophilus congolensis* infection in a calf based on modified in vitro disk diffusion test. *Arq. Inst. Biol.*, **84**, 1-7 (2017). DOI: 10.1590/1808-1657000382017.
7. Olaogun, S.C. and Onwuzuruike, K.J. Incidence and biochemical parameters of dermatophilosis in Nigerian cattle breeds from livestock markets, Oyo state, Nigeria. *Open Vet. J.*, **8**, 35-39 (2018). DOI: 10.4314/ovj.v8i1.6.
8. Or, M.E., Dodurka, T., Ozgur, Y., Kayar, A., Ikiz, S. and Tan, H. The first study on dermatophilosis in Turkey. *J. Fac. Vet. Med. Univ. Istanbul.*, **25**, 273-279 (1999).
9. Sekin, S., Elitok, O.M., Elitok, B. and Suay, A. Natural ovine dermatophilosis: clinical aspects and efficacy of penicillin/streptomycin treatment. *Turk. J. Vet. Anim. Sci.*, **26**, 1013-1019 (2002).
10. Iliyasu, D., Munir, A.S., Auwal, U., Omonike, O.S., Mustapha, R.A. and Ahmed, I. Consequences of chronic dermatophilosis on semen quality and reproductive performance of Friesian bull in multipurpose farm in Zaria, Nigeria. *Int. J. Livest. Res.*, **5**, 46-53 (2015). DOI: 10.5455/ijlr.20150527020833.
11. Yeruham, I., Elad, D. and Perl, S. Dermatophilosis in goats in the Judean foothills. *Revue Med. Vet.*, **12**, 785-786 (2003).
12. Ananda, C.M., Jayalakshmi, K., Ponnusamy, P., Manickam, R. and Ronald, B.S.M. *Dermatophilus congolensis* infection in sheep and goats in Delta region of Tamil Nadu. *Vet. World.*, **10**, 1314-1318 (2017). DOI: 10.14202/vetworld.2017.1314-1318.
13. Or, M.E. and Bakirel U. Skin Disease. In: Gul Y. (Ed.), *Internal Diseases of Ruminants*, 3rd Edition. Medipress, Malatya. 454-457 (2012).
14. Tresamol, P.V. and Saseendranath, M.R. Diagnosis of dermatophilosis in dairy cattle in Kerala, India. *Indian J. Anim. Res.*, **49**, 709-712 (2015). DOI: 10.18805/ijar.5587.
15. Covarrubias, A.C., Zaragoza, C.S., Bucio, A.M., Aparicio, E.D. and Olivares, R.A.C. Outbreak of *Dermatophilus congolensis* in grazing beef cattle in Northeastern Mexico: first report. *J. Veterinar. Sci. Technol.*, **6**, 222-225 (2015). DOI: 10.4172/2157-7579.1000222.
16. Gocmen, H. and Sen, A. *Dermatophilus congolensis* infection in a sheep-goat herd. *Uludag Univ. J. Fac. Vet. Med.*, **32**, 63-66 (2013).
17. Bauer, A.U., Kirby, J.C. and Sherris, M.T. Antibiotic susceptibility testing by a standardized single disc method. *J. Clin. Pathol.*, **45**, 493-494 (1966). DOI: 10.1093/ajcp/45.4_ts.493.
18. Tresamol, P.V. and Saseendranath, M.R. Antibigram of *Dermatophilus congolensis* isolates from cattle. *Int. J. Livest. Res.*, **3**, 117-121 (2013).
19. Clinical and Laboratory Standards Institute (CLSI). Performance Standards for Antimicrobial Susceptibility Testing; M100-S27. *Clinical and Laboratory Standards Institute*, Wayne, PA, (2017).
20. Yeruham, I., Elad, D., and Perl, S. Dermatophilosis in small ruminants in Israel. *Israel J. Vet. Med.*, **49**, 161-164 (1994).
21. Vieira, V.D., Correa, F.R., Vilela, V.L.R., Medeiros, M.A., Morais, D.F., Santos, A., Feitosa, T.F. and Almeida Neto, J.L. Dermatophilosis in sheep raised under rotational grazing systems on irrigated pastures in the Brazilian semi-arid region. *Cienc. Rural*, **47**, 1-7 (2017). DOI: 10.1590/0103-8478cr20160932.
22. Abdo, J. and Pal, M. Clinical and microbiological observations on caprine and ovine dermatophilosis. *Intas Polivet.*, **14**, 375-377 (2013).
23. Olaogun, S.C. and Jeremiah, O.T. Clinico-haematological features of dermatophilosis in indigenous breeds of cattle in Ibadan, Nigeria. *Niger. Vet. J.*, **39**, 151-160 (2018). DOI: 10.4314/nvj.v39i2.7.
24. Tresamol, P.V. and Saseendranath, M.R. Clinical and haemato-biochemical studies on generalised dermatophilosis in cattle. *Ind. J. Vet. Anim. Sci. Res.*, **43**, 206-210 (2014).

-
25. Gaulier, P.R., Blancou, J.M., Bourdin, P., Ribot, J.J., Ramisse, J. and Serres, H. Contribution to the serological and physo-pathological study of bovine streptothricosis. *Rev. Elev. Med. Vet. Pays. Trop.*, **25**, 171-185 (1972).
 26. Hamid, M.E. and Musa, M.S. The treatment of bovine dermatophilosis and its effects on some haematological and blood chemical parameters. *Rev. Sci. Tech.*, **28**, 1111-1118 (2009). DOI: 10.20506/rst.28.3.1954
 27. Barre, N., Matheron, G., Lefevre, P.C., Lechoff, C., Rogez, B., Roger, E., Martinez, D. and Sheikhoudou, C. *Dermatophilus congolensis* infection in cattle in French West Indies: Characteristics of the lesions and the serological response. *Rev. Elev. Med. Vet. Pays. Trop.*, **41**, 129-138 (1988).
 28. Gbodi, T.A. Serum mineral states of normal and *Dermatophilus congolensis* infected friesland calves. *Bull. Anim. Hlth. Prod. Afr.*, **28**, 348-350 (1980).
 29. Russell, K.E. and Roussel, A.J. Evaluation of the ruminant serum chemistry profile. *Vet. Clin. Food Anim.*, **23**, 403-426 (2007). DOI:10.1016/j.cvfa.2007.07.003.
 30. Melillo, A. Rabbit clinical pathology. *J. Exot. Pet Med.*, **16**, 135-145 (2007). DOI:10.1053/j.jepm.2007.06.002.
 31. Turgut, K. Veterinary Clinic Laboratory Diagnosis. 2nd edition. Bahcivanlar, Konya. 372-388 (2000).
 32. Osman, S.A. Clinical and therapeutic studies on dermatophilosis of sheep and goats in Quassim, Kingdom of Saudi Arabia. *Assiut. Vet. Med. J.*, **61**, 51-55 (2015).
 33. Ranjithkumar, M., Saravanan, M., Krishnakumar, S., Raj, H.P., Saahithya, R. and Satheshkumar, S. Dermatophilosis in a buffalo: A case report. *Buffalo Bull.*, **37**, 253-258 (2018).